

Successful Therapy of Vulvodynia with Local Anesthetics: A Case Report

Stefan Weinschenk^{a,d} Kerstin Brocker^a Lorenz Hotz^b Thomas Strowitzki^a Stefanie Joos^c
for the HUNTER (Heidelberg University Neural Therapy Education and Research) Group

^a Department of Gynecological Endocrinology and Fertility Disorders,

^b Department of Anesthesiology and Intensive Care,

^c Department of General Medicine, University of Heidelberg,

^d Karlsruhe, Germany

Keywords

Vulvodynia · Vulvar vestibulitis syndrome · Focus · Stoerfeld · Interference field · Local anesthetics · Neural therapy · Procaine · Therapeutic nerve block · Chronic inflammation

Schlüsselwörter

Vulvodynie · Vulvares Vestibulitis-Syndrom · Fokus · Störfeld · Lokalanästhesie · Neuraltherapie · Procain · Therapeutische Nervenblockade · Chronische Entzündung

Summary

Background: Vulvodynia often occurs with unexplained vulvar pain and hyperesthesia, sexual dysfunction, and psychological disability, lacking an organic or microbiological substrate. **Case Report:** A 25-year-old woman with generalized, unprovoked vulvodynia for 12 years was treated repeatedly with procaine 1% for 14 sessions after she had previously had numerous unsatisfying multidisciplinary treatments. We observed a decrease in pain scores on the visual analogue scale (VAS) from initially 8–9 to presently 0–2. Injection sites were: Head's zones and trigger points of the lower abdomen, regional hypogastric ganglia, bilateral maxillary sinus, and scars of the lower jaw. No major adverse events were observed. Injections to remote sites improved symptoms more strongly than local or regional therapy. After a 3-year follow-up the patient is free of symptoms. **Conclusion:** Therapy with local anesthetics (TLA, neural therapy) can be a useful additional therapy in complicated cases of vulvodynia. Further studies on the underlying mechanism of injections into remote foci (interference field, stoerfeld) and the effectiveness of TLA in chronic pain syndromes should be performed.

Zusammenfassung

Hintergrund: Die Vulvodynie geht einher mit vulvären Schmerzen und Hyperästhesie unklarer Ursache sowie mit sexueller Dysfunktion und psychosozialen Störungen; meist lassen sich keinerlei organische oder mikrobiologische Ursachen identifizieren. **Fallbericht:** Wir behandelten eine 25-jährige Patientin mit Vulvodynie mittels Neuraltherapie (Therapeutische Anwendung von Lokalanästhetika) über 14 Sitzungen. Die Patientin hatte zuvor seit über 12 Jahren an Vulvabeschwerden gelitten, zuletzt mit zunehmender Generalisierung und Dauerschmerz. Verschiedene, auch interdisziplinäre Therapien hatten keinerlei Verbesserung gebracht. Unter Neuraltherapie kam es zu einer Schmerzreduzierung auf der Visuellen Analogskala (VAS 0–10) von 8–9 auf zuletzt 0–2. Folgende Injektionen wurden durchgeführt: Head'sche Zonen und Triggerpunkte des Genitale, suprapubische und parazervikale Injektion in den Bereich des Frankenhäuser-Ganglions, Nasennebenhöhlen und Narben von einer Umstellungsosteotomie des Kiefers. Es wurden keine schwerwiegenden Nebenwirkungen beobachtet. Ferninjektionen führten zu einer deutlicheren und länger anhaltenden Besserung als lokale und segmentale Injektionen. 2 Jahre nach Therapieende ist die Patientin weiterhin beschwerdefrei. **Schlussfolgerung:** Neuraltherapie kann eine sinnvolle Ergänzung bei schwerwiegenden Verläufen von Vulvodynie sein. Weitere Studien sind erforderlich, um die zugrundeliegenden Mechanismen, die Wirkung von Ferninjektionen in Störfelder und die Wirksamkeit der Therapie mit Lokalanästhetika zu erforschen.

Introduction

Vulvodynia often presents with unexplained vulvar pain and hyperesthesia, sexual dysfunction, and psychological disability, lacking an organic or microbiological substrate. Prevalence varies from 9–12% [1]. Vulvodynia can have an acute onset, sometimes linked to episodes of vaginitis or therapeutic procedures such as cryosurgery (provoked vulvodynia) [2]. Biopsy usually reveals normal tissue histology, yet sometimes an increased number of nerve fibers [3]. Pain is described as a burning and stinging irritation or rawness, but not itching [4]. A classification of vulvodynia was published by the British Society for the Study of Vulval Disease (BSSVD) [5].

Satisfying therapeutic options are scarce. In general, antibacterial, antifungal, and analgetic drugs are frequently applied, such as desensitizing ointments based on capsaicin [6], systemic analgesics (e.g., opiates), anticonvulsives (pregabalin), surgical excision [7], and/or antidepressants [8], all with limited effect. Therefore, the BSSVD advocates a holistic approach, not only focusing on the primary site of pain [5]. These authors suggest a therapy trial with local anesthetics (LA) in all vulvodynia subsets. Therapy with local anesthetics (TLA), or neural therapy (NT), is commonly used in Central Europe [9, 10]. We performed TLA/NT in this desperate case.

Case Report

A 25-year-old Caucasian woman suffering from generalized, unprovoked vulvodynia for 12 years consulted our gynecological practice in October 2007 with discomfort in the genital area, hyperalgesia, and recurring burning sensations around the mons pubis and the outer labia, which radiated to the lower abdomen. Pain scores during the last 2 years varied from 7–9 in a visual analogue scale (VAS) of 0–10 [11]. The VAS is a frequently used quantification system in patients suffering from chronic vulvodynia [12].

The patient was unable to cycle or to wear tight clothes. The use of female hygiene products and sexual intercourse were made impossible by the before-mentioned symptom complex. Repeated microbiological testing did not show any pathological microorganisms. Numerous local treatments with fatty and watery ointments, cotrimazol, estriol, or antibiotics had been performed unsuccessfully. In 2003 treatment with topical antibiotics (gentamycine) and skin ointments (olive oil, betaisodona, zinc ointment) as well as topical corticosteroids (triamcinolon) was initiated, but brought no significant relief. In 2004 a coagulation of her labia was performed, resulting in further deterioration. Histological evaluation at that time showed nonspecific inflammation with hyperkeratosis and an increased number of nerve cells in the affected area, leading to the diagnosis of a vulva vestibulitis syndrome (VVS). Treatment with gabapentin up to 300mg/d over a period of 1 year did not improve the situation. Capsaicin had to be interrupted due to side effects. Further treatment with amitriptylin 50 mg for 2 months was started, but non-effective.

There is no history of allergy, metabolic diseases, smoking, or drug abuse. The patient had normal body weight (BMI = 19), a regular menstrual period, no pregnancy, and no major surgery except for a surgical correction of her prognatism with mandible wedge excision in 2001. After this surgery, the patient reported an immediate and long-lasting deterioration of her vulvar complaints. The possible importance of this notification will be discussed later.

Clinical Examination

Infectious (bacteria, chlamydia, parasites, or candida), atopic, or other dermatological diseases were excluded by clinical examination and laboratory tests. Psychosocial exploration did not show signs of psychic illness or major psychosocial stress except for disillusion concerning the success of any further therapy. There were no signs of pelvic floor muscle dysfunction.

Treatment

After obtaining the patient's informed consent, injections of local anesthetics (TLA) to different sites were repeated with increasing time intervals from 1 per week up to 1 every 4–8 weeks. Injection sites were determined and techniques performed according to published knowledge of TLA [13, 14], using procaine in a 1% saline solution with benzoyl alcohol as a preservative agent (Steigerwald Inc., Darmstadt, Germany). The quantity of applied LA ranged from 3–15 ml (maximum dose 3 mg/kg BM). Injection procedures are described in table 1.

During NT, no major psychosocial events occurred and no other treatments were initiated. The patient had no changes in her psychosocial background (same job, same partner) since the beginning of NT.

Results

Clinical Course of Therapy

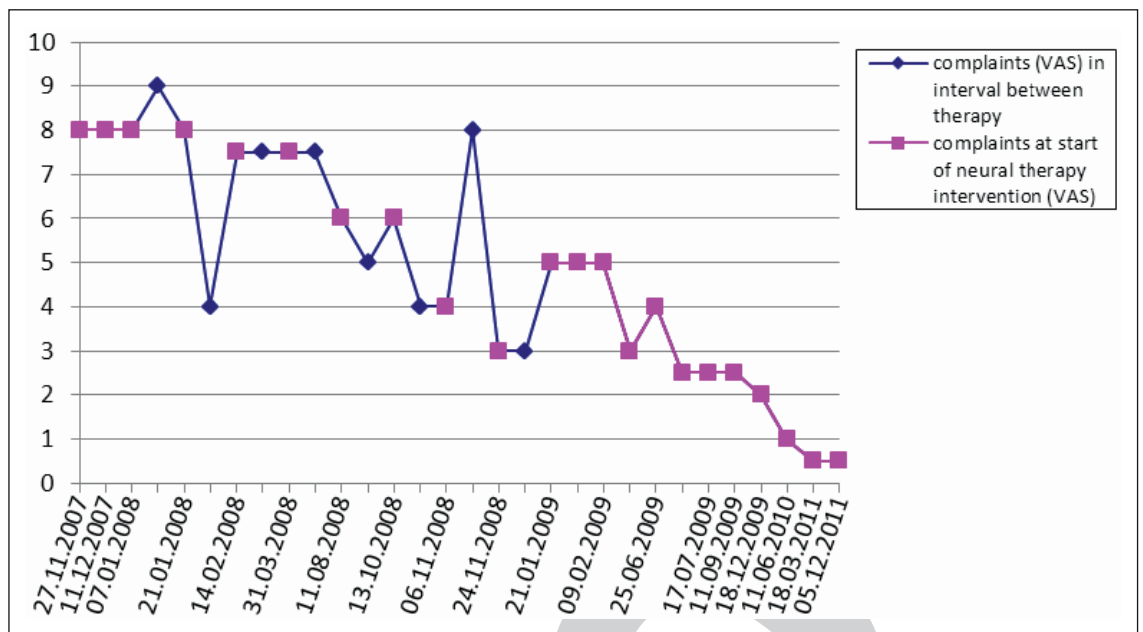
Ongoing analgetic therapy was not interrupted until TLA became successful. Injections to regional reflex and trigger points did not have a significant effect. Vaginal injection into the region of the hypogastric ganglion (Frankenhäuser's ganglion) on January 21st, 2008 led to a first long-lasting (> 2 weeks) pain relief from VAS 8 to an average of 6.

After additionally injecting LA into the patient's bilateral maxillary sinus, further relief of pain was observed, from VAS 6 to an average of 5.

A pre-existing vaginal cyst was surgically removed on July 7th, 2008. Histological examination showed fibrotic inflammation without any evidence of malignant behavior. Following surgery, there was an interim deterioration of vulvar complaints. In August 2008, a combination of injections into the hypogastric plexus and the cavum retzii led to an immediate improvement after therapy, which however did not last more than 4 days. This improvement lasting for some days could be repeated several times.

In order to further improve the clinical effect of therapy, a combination of genital injection sites with injections to the mandibular nerve and the palatine arch in November 2008 led to a pain relief to VAS 3 for the first time, lasting for more than 2 weeks. Omitting the remote injections into the oral region in January 2009 did not relieve complaints. Only after repeating this combination in February 2009, was a successful relief of pain observed reaching VAS 1–2 (fig. 1). After continuous improvement from February 2009 onwards, therapy intervals could be prolonged step-by-step up to several months.

Fig. 1. Course of complaints since start of therapy. Y-scale: VAS (0–10). Square dots: Complaints (VAS) immediately after each neural therapy intervention. Rhomboid dots: Complaints (VAS) in the time interval between therapy appointments, according to the patient's estimation of the average VAS during the last weeks. After injections, short-time improvement for some days (21.01.2008, 13.10.2008) as well as short-time deterioration for 1–2 days



(06.11.2008, after vaginal surgery for a vaginal cyst) could be seen. VAS 0–2 remained constant without intermediate deterioration since 18.12.2009.

Current State after Therapy

Since 2010 the patient has remained almost completely free of symptoms (VAS 0–1) without any need for drug therapy (fig. 1). A prophylactic refreshing of TLA is performed every 4–6 months, most recently in December 2011. All findings on gynecological clinical examination (e.g., Pap smear, microbiology) are normal. Bike-riding, swimming, use of sanitary tampons, and vaginal intercourse are possible without complaints. The patient gave us informed consent for pseudonymic data evaluation.

Side Effects

Injections with procaine 1% were overall tolerated well. Occasionally mild dizziness and orthostatic dysregulation lasting 4–10 min occurred. Nausea and dragging abdominal pain occurred only once after the 9th therapy session in November 2008 for less than 1 day, resolving spontaneously without further treatments.

Discussion

We report the case of a patient with long-lasting vulvodynia successfully treated with repeated injections of procaine. Systemic treatment with opioids and anticonvulsants could be stopped completely after improvement of symptoms.

There is some evidence that a systemic approach like acupuncture [15], or transcutaneous electrical nerve stimulation [16], is effective in treating vulvodynia. TLA also implies a

systemic approach similar to acupuncture. Many data in basic research have been accumulated on possible effects of LA beyond sodium ion channel blockage, such as anti-inflammatory [17, 18] and immune-stimulating effects [19]. Clinical data of 227 publications about positive effects of LA in chronic inflammation have been summarized in 2006 [19]. Vulvodynia may be a form of chronic sterile neurogenic inflammation [20]. Kevin Tracey reported that LA can interrupt the release of proinflammatory substances at the terminal plate of the neuron [21]. A review of the literature on these 'alternative effects' of LA was published in 2012 [22]. For these reasons, local anesthetics (TLA/NT) may be useful in treating vulvodynia.

However, unspecific effects like patients' expectations may play a crucial role in complex interventions such as NT [23]. It is remarkable that the breakthrough of the therapy effect was achieved only after injections into a remote area, the lower jaw, and was unexpected by the patient. The patient's general lack of hope may therefore have played only a minor role.

The rationale of remote injections was the patient's history of deterioration of complaints after jaw surgery in 2001. A 'diagnostic' injection into the region of the respective scars of the lower jaw was followed by a sudden and long-lasting improvement. What was the nature of this effect?

NT can be administered at different types of sites. The most common method is injecting into the area of complaints (local therapy). In segmental neural therapy injections are applied into Head's zones, trigger points, reference points of the respective meridians, in and around related joints, and in soft tissue, all within the same spinal segment. Third, regional therapy may influence neuroanatomical control instances,

whereby regional ganglia may be addressed in order to re-establish normal vegetative function of the respective area. In our patient, we used regional or ganglia therapy by injections into the hypogastric ganglion. Another method is systemic therapy, which can be successful in acute inflammation [24].

Finally, the most complex mode of administration is injecting LA into remote areas which seem to have no neuroanatomical connection to the disturbed area. The rationale of influencing these so-called störfelder (interference fields, German: 'Störfelder' [25]) is a hologram-like connection of every area of the body to any other one [25]. This concept is well known from Traditional Chinese Medicine. Thus, a holistic approach is necessary to reveal distant disturbances chronically influencing other regions of the body. In our case, the jaw scar from major dental surgery may have been such a störfeld for the genital region. Similar observations were made by Marco Schmidt and colleagues [26] with successful treatment of musculoskeletal diseases by LA injections into the wisdom teeth, also inducing remote effects according to the störfeld concept.

We do not know the causes of these remote effects. A first systematic description of remote effects was published in 1953 by Max Ratschow [27]. The connection between trigeminal and vagal nuclei [28] may serve as a toggle between facial afferent and abdominal efferent nerves, thus connecting dental, cervical, and abdominal areas. Further studies will be necessary to reveal this interesting, but somewhat irritating concept of connections throughout the body.

Advantages and Disadvantages of the NT Approach

TLA/NT may be a useful additional therapy option in such difficult-to-treat diseases as vulvodynia. LA have few side effects [29], and numerous gynecologists and anesthesiologists are familiar with the injection techniques used in this case [30]. However, there are some limitations of this therapy regimen. Several treatment appointments may be necessary. The danger of fixating the patient to invasive techniques should be kept in mind. Therefore, psychosocial exploration is recommended before starting any invasive therapies. Therapeutic

success in NT does not follow a linear curve, as we could see in our case. Thus, patients and physicians should be aware of transient deterioration in the course of therapy.

Furthermore, NT implies different therapeutic regimens for any individual patient. Intralesional injections, as suggested by the BSSVD [5], based on data of Murat Dede and colleagues [31], may not be sufficient alone. As this case shows, a thorough history may be necessary in difficult cases to achieve a breakthrough with remote techniques. However, the basis for these injections, the thus far unproven störfeld concept of NT, is an obstacle for many physicians to become familiar with this therapy. Some promising data have been collected from gnathology, where neuralgia-inducing cavitation osteonecrosis (NICO) has been named after its capability of inducing remote neuralgia [32]. However, methodologically rigorous clinical research will be necessary to elucidate the underlying focal theory of chronic diseases.

Although many physicians in Central Europe use TLA/NT [9], its rationale is unclear. The widespread use and high patient satisfaction [10], in contrast to the lack of scientific data, call for further studies. Our findings may contribute to a better understanding of the clinical effects of TLA/NT, which is requisite for designing clinical studies. This successful treatment of a severe case of vulvodynia may lead to the careful assumption that NT can be a sufficient treatment option, whether it is applied primarily or after numerous insufficient standard procedures.

Acknowledgements

The authors wish to thank Stefan Fiedler, a medical student at the University of Heidelberg, for his help in extracting the patient's charts.

Disclosure Statement

Stefan Weinschenk is a member of the scientific board of the International Society of Neural Therapy according to Huneke Regulation Therapy (IGNH e.V.) and of the scientific chapter of the International Council of Medical Acupuncture and Related Techniques (ICMART). None of the other authors declare conflicts of interest.

References

- 1 Reed BD, Harlow SD, Sen A, Legocki LJ, Edwards RM, Arato N, Haefner HK: Prevalence and demographic characteristics of vulvodynia in a population-based sample. *Am J Obstet Gynecol* 2012;206:170.e1-9.
- 2 Farmer MA, Taylor AM, Bailey AL, Tuttle AH, MacIntyre LC, Milagrosa ZE, Crissman HP, Bennett GJ, Ribeiro-da-Silva A, Binik YM, Mogil JS: Repeated vulvovaginal fungal infections cause persistent pain in a mouse model of vulvodynia. *Sci Transl Med* 2011;3:101ra91.
- 3 Tympanidis P, Terenghi G, Dowd P: Increased innervation of the vulvar vestibule in patients with vulvodynia. *Br J Dermatol* 2003;148:1021-1027.
- 4 Donders G, Bellen G: Characteristics of the pain observed in the focal vulvodynia syndrome (VVS). *Med Hypotheses* 2012;78:11-14.
- 5 Nunns D, Mandal D, Byrne M, McLelland J, Rani R, Cullimore J, Bansal D, Brackenbury F, Kirtschig G, Wier M: Guidelines for the management of vulvodynia. *Br J Dermatol* 2010;162:1180-1185.
- 6 Murina F, Radici G, Bianco V: Capsaicin and the treatment of vulvar vestibulitis syndrome: a valuable alternative? *MedGenMed* 2004;6:48.
- 7 Andrews JC: Vulvodynia interventions – systematic review and evidence grading. *Obstet Gynecol Surv* 2011;66:299-315.
- 8 Khandker M, Brady SS, Vitonis AF, Maclehorse RF, Stewart EG, Harlow BL: The influence of depression and anxiety on risk of adult onset vulvodynia. *J Womens Health (Larchmt)* 2011;20:1445-1451.
- 9 Joos S, Musselmann B, Szecsenyi J: Integration of complementary and alternative medicine into family practices in Germany: results of a national survey. *Evid Based Complement Alternat Med* 2011; 2011:495813.

- 10 Mermod J, Fischer L, Staub L, Busato A: Patient satisfaction of primary care for musculoskeletal diseases: a comparison between neural therapy and conventional medicine. *BMC Complement Altern Med* 2008;8:33.
- 11 Grant S, Aitchison T, Henderson E, Christie J, Zare S, McMurray J, Dargie H: A comparison of the reproducibility and the sensitivity to change of visual analogue scales, Borg scales, and Likert scales in normal subjects during submaximal exercise. *Chest* 1999;116:1208–1217.
- 12 Ventolini G: Measuring treatment outcomes in women with vulvodynia. *J Clin Med Res* 2011;3:59–64.
- 13 Weinschenk S: *Handbuch Neuraltherapie – Diagnostik und Therapie mit Lokalanästhetika*. München, Elsevier, 2010.
- 14 Jankovic D: *Regionalblockaden und Infiltrationstherapie*. Berlin, ABW Wissenschaftsverlag, 2008.
- 15 Powell J, Wojnarowska F: Acupuncture for vulvodynia. *J R Soc Med* 1999;92:579–581.
- 16 Murina F, Bianco V, Radici G, Felice R, Di Martino M, Nicolini U: Transcutaneous electrical nerve stimulation to treat vestibulodynia: a randomised controlled trial. *BJOG* 2008;115:1165–1170.
- 17 Hollmann MW, Herroeder S, Kurz KS, Hoeneemann CW, Struemper D, Hahnenkamp K, Durieux ME: Time-dependent inhibition of G protein-coupled receptor signaling by local anesthetics. *Anesthesiology* 2004;100:852–860.
- 18 Hahnenkamp K, Durieux ME, Hahnenkamp A, Schauerte SK, Hoeneemann CW, Vegh V, Theilmeier G, Hollmann MW: Local anaesthetics inhibit signalling of human NMDA receptors recombinantly expressed in *Xenopus laevis* oocytes: role of protein kinase C. *Br J Anaesth* 2006;96:77–87.
- 19 Cassuto J, Sinclair R, Bonderovic M: Anti-inflammatory properties of local anesthetics and their present and potential clinical implications. *Acta Anaesthesiol Scand* 2006;50:265–282.
- 20 Tracey KJ: Physiology and immunology of the cholinergic antiinflammatory pathway. *J Clin Invest* 2007;117:289–296.
- 21 Tracey KJ: Reflex control of immunity. *Nat Rev Immunol* 2009;9:418–428.
- 22 Weinschenk S: Therapy with local anaesthetics – the neural therapy approach. A review. *Acupunct Rel Ther* 2012;1:25–32.
- 23 Di Blasi Z, Harkness E, Ernst E, Georgiou A, Kleijnen J: Influence of context effects on health outcomes: a systematic review. *Lancet* 2001;357:757–762.
- 24 Layer P, Bronisch HJ, Henniges UM, Koop I, Kahl M, Dignass A, Ell C, Freitag M, Keller J: Effects of systemic administration of a local anesthetic on pain in acute pancreatitis: a randomized clinical trial. *Pancreas* 2011;40:673–679.
- 25 Mastalier O, Weinschenk S: Störfeld und Herdgeschehen; in Weinschenk S (ed): *Handbuch Neuraltherapie. Diagnostik und Therapie mit Lokalanästhetika*. München, Elsevier, 2010, pp 137–168.
- 26 Schmidt M, Hennke T, Knochel M, Kurten A, Hierholzer J, Daniel P, Bittmann F: Can chronic irritations of the trigeminal nerve cause musculoskeletal disorders? *Forsch Komplementmed* 2010;17:149–153.
- 27 Ratschow M: Efficiency of therapeutic anesthesia (in German). *Acta Neuroveg (Wien)* 1951;3:198–210.
- 28 Sessle BJ, Hu JW, Amano N, Zhong G: Convergence of cutaneous, tooth pulp, visceral, neck and muscle afferents onto nociceptive and non-nociceptive neurones in trigeminal subnucleus caudalis (medullary dorsal horn) and its implications for referred pain. *Pain* 1986;27:219–235.
- 29 Cousins MJ, Bridenbaugh PO (eds): *Neural Blockade in Clinical Anesthesia and Management of Pain*. Philadelphia, Lippincott-Raven Publishers, 1998.
- 30 Ling FW, Slocumb JC: Use of trigger point injections in chronic pelvic pain. *Obstet Gynecol Clin North Am* 1993;20:809–815.
- 31 Dede M, Yenen MC, Yilmaz A, Baser I: Successful treatment of persistent vulvodynia with submucous infiltration of betamethasone and lidocaine. *Eur J Obstet Gynecol Reprod Biol* 2006;124:258–259.
- 32 Bouquot JE, Roberts AM, Person P, Christian J: Neuralgia-inducing cavitation osteonecrosis (NICO). Osteomyelitis in 224 jawbone samples from patients with facial neuralgia. *Oral Surg Oral Med Oral Pathol* 1992;73:307–319; discussion 319–320.